

CASE REPORT

Oculomotor Nerve Palsy in a Patient with a Ruptured Middle Cerebral Artery Aneurysm

Suguru Yokosako, Yuichiro Kikkawa, Ririko Takeda, Toshiki Ikeda, and Hiroki Kurita

Department of Cerebrovascular Surgery, Saitama Medical University International Medical Center, Saitama, Japan

Abstract : We describe a case of acute oculomotor nerve palsy caused by a ruptured middle cerebral artery (MCA) aneurysm. A 59-year-old female presenting with headache and nausea was admitted to our hospital. Her consciousness was alert, and had no other neurological deficit without left oculomotor nerve palsy. A computed tomography (CT) showed SAH extending from left sylvian cistern to basal cistern. CT angiography revealed a left MCA aneurysm which protruded toward internal carotid artery. The patient was successfully treated with surgical clipping. The oculomotor nerve palsy resolved immediately after the surgery. Perioperative radiological evaluation revealed that there were no evidence of midbrain hemorrhage or stroke, vessel anomaly of basilar, posterior cerebral or superior cerebellar artery, vasospasm, and uncal herniation. Furthermore, intraoperative findings revealed that the aneurysm was projected toward the affected carotid cistern and oculomotor nerve. From these findings and time course of oculomotor nerve palsy, it is suggested that the jet flow of bleeding from the ruptured MCA aneurysm caused oculomotor nerve palsy in the patient. *J. Med. Invest.* 64 : 165-167, February, 2017

Keywords : oculomotor nerve palsy, middle cerebral artery aneurysm, subarachnoid hemorrhage

INTRODUCTION

Patients with acute subarachnoid hemorrhage (SAH) occasionally present with isolated oculomotor nerve palsy. The majority of those patients have ruptured aneurysms of the internal carotid-posterior communicating artery junction or basilar artery-superior cerebellar artery junction, reflecting the anatomical proximity of the affected vessels and the oculomotor nerve (1-3). Conversely, solitary oculomotor nerve palsy due to rupture of an aneurysm that is far from the nerve is extremely rare. Here we describe a case of oculomotor nerve palsy caused by rupture of a middle cerebral artery (MCA) bifurcation aneurysm. The mechanism of this fairly rare condition in association with SAH is discussed.

CASE REPORT

A 59-year-old female experienced sudden headache and nausea and was referred to our institution 14 hours after the onset. She had a history of hypertension and malignant rheumatoid arthritis that had been adequately controlled by medication. She had no history of diabetes mellitus, heart disease, stroke, or cancer. She had no family history of SAH, and no habit of smoking or alcohol. On arrival, she was alert and well oriented. She had no neurological deficit except for left external/internal oculomotor nerve palsy, including ptosis, pupillary dilatation, and loss of direct/indirect light reflexes. Computed tomography (CT) scans showed a diffuse thick SAH, especially in the left sylvian fissure (Figure 1). Three-dimensional CT angiography demonstrated a small, medially projecting, left MCA bifurcation aneurysm with a maximum diameter of 3.5 mm (Figure 2). No other aneurysms were identified. There were no vessel anomalies including the tortuosity or dolichoectasia

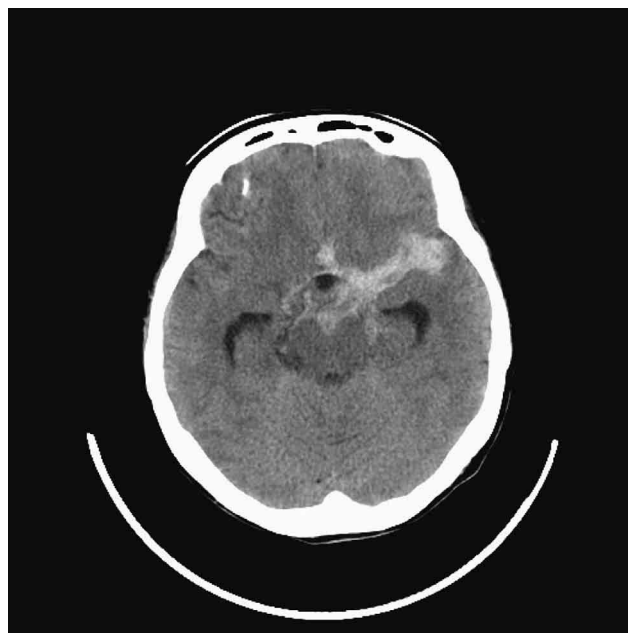

Figure 1.
Initial CT showing localization of the subarachnoid hemorrhage.

of the posterior cerebral artery (PCA), superior cerebellar artery (SCA), posterior communicating artery or basilar artery.

The patient underwent an emergent craniotomy and repair of the aneurysm. During surgery, the MCA aneurysm was found to be ruptured and was successfully clipped. A small protrusion at the tip of the aneurysm dome toward the carotid cistern was evident and thought to be the bleeding point. Subsequently, subarachnoid clots in the sylvian and basal cisterns were adequately removed, and careful inspection of the carotid and basilar cisterns around the left oculomotor nerve indicated no carotid or basilar artery

Received for publication February 1, 2016 ; accepted August 10, 2016.

Address correspondence and reprint requests to Yuichiro Kikkawa, MD, PhD, 1397-1 Yamane, Hidaka-city, Saitama, 350-1241 Japan and Fax : +81-042-984-4740.

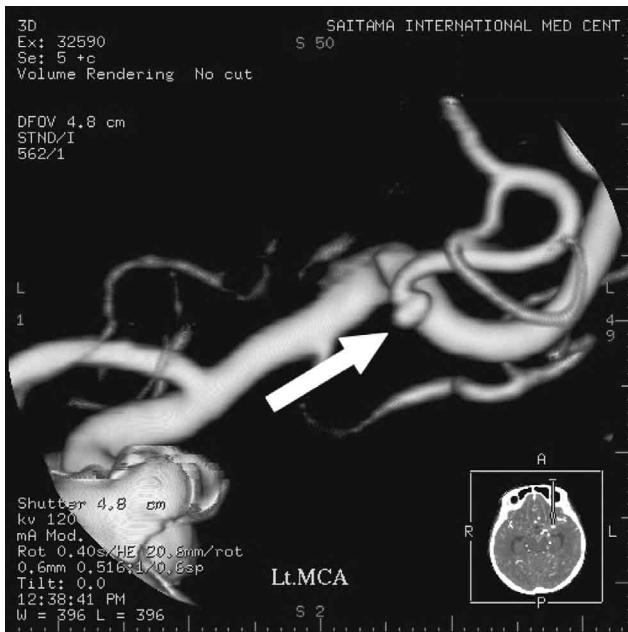


Figure 2.
3-dimensional CT angiogram demonstrating the aneurysm in the left MCA. The rupture point (arrow) is directed toward the internal carotid artery.

aneurysms and no compression of oculomotor nerve by PCA or posterior communicating artery.

After surgery, the patient recovered well, and the oculomotor nerve palsy was completely resolved immediately. Subsequent CT showed no abnormal lesions in the midbrain. She was discharged as ambulatory 26 days after surgery without neurological deficits.

DISCUSSION

Ruptured aneurysms distant from the oculomotor nerve are known to cause acute oculomotor nerve palsy. Reported localizations for such aneurysms include the anterior communicating artery, anterior cerebral artery, contralateral internal carotid artery, and MCA (4-9). The oculomotor nerve palsy without direct aneurysm compression in SAH can be caused by increased intracranial pressure (ICP), uncal herniation, vasospasm, midbrain hemorrhage or infarction, jet flow of bleeding from aneurysm, and oculomotor nerve compression by the hematoma or tortuous arteries including posterior communicating artery or PCA (4-13). In our case, ICP elevation was not remarkable, therefore external decompression was not performed. Furthermore, preoperative radiological evaluation excluded uncal herniation, vasospasm, and midbrain hemorrhage or infarction, and vascular anomaly of PCA, SCA, posterior communicating artery or basilar artery. Although there was a diffuse thick SAH in the basal cistern on admission CT scan, we often experience such amount of SAH in the basal cistern without oculomotor nerve palsy in ruptured MCA cases. These findings support the idea that oculomotor nerve palsy may be caused by the jet flow of bleeding from ruptured MCA aneurysm. Furthermore, it is important that our case showed prompt recovery of oculomotor nerve palsy. Saito *et al.* reported the jet flow of bleeding from internal carotid artery aneurysm might cause contralateral oculomotor nerve palsy (6). Kim *et al.* also reported the jet flow of bleeding by the second rupture from MCA aneurysm might cause oculomotor nerve palsy (7). These cases showed prompt recovery of oculomotor

nerve palsy similar to ours. On the other hand, oculomotor nerve palsy due to direct aneurysm compression or stroke recovers very slowly after repair of the aneurysm (13). Therefore, the clinical course of the present case also supports the idea that oculomotor nerve palsy may be caused by the jet flow of bleeding. Finally, we intraoperatively confirmed that the bleeding point of the aneurysm was directed toward the oculomotor nerve. Accordingly, the oculomotor nerve palsy is suggested to be caused by the jet flow of bleeding from ruptured MCA aneurysm which is directed toward the oculomotor nerve.

Although the small number of reported cases precludes statistical analysis, accumulated clinical data suggest that the characteristic features of oculomotor nerve palsy that is associated with a ruptured aneurysm in a distant location include: 1) no evidence of midbrain hemorrhage or infarction, remarkable elevation of ICP, vasospasm, hematoma compression, anomaly of basilar artery, PCA, SCA or posterior communicating artery, and uncal herniation; 2) aneurysm projection toward the affected carotid cistern and oculomotor nerve; and 3) prompt recovery of the symptom within a few days.

Our case serves as a reminder that oculomotor nerve palsy can be a false localizing sign of a ruptured aneurysm in SAH patients. This unusual occurrence suggests an alternative explanation of oculomotor nerve palsy that is not directly related to aneurysmal compression.

CONFLICTS OF INTEREST

No work resembling the enclosed article has been published for publication elsewhere. We certify that each author has made a substantial contribution so as to qualify for authorship as detailed at the end of the manuscript. We have disclosed all financial support for our work and other potential conflicts of interest.

ACKNOWLEDGEMENT

This study was supported in part by JSPS KAKENHI Grant numbers 25462235 and 26461278.

REFERENCES

1. Biousse V, Newman NJ: Third Nerve palsies. *Semin Neurol* 20: 55-74, 2000
2. Fujiwara S, Fujii K, Nishio S, Matsushima T, Fukui M: Oculomotor nerve palsy in patients with cerebral aneurysms. *Neurosurg Rev* 12: 123-132, 1989
3. Keane J: Aneurysms and third nerve palsies. *Ann Neurol* 14: 696-697, 1983
4. Aiba T, Fukuda M: Unilateral Oculomotor Nerve paresis associated with anterior communicating artery aneurysm rupture -two case reports-. *Neurol Med Chir (Tokyo)* 43: 484-487, 2003
5. Fairbanks C, White JB: Oculomotor nerve palsy in the setting of an anterior cerebral A2 segment aneurysm. *J NeuroIntervent Surg* 3: 74-76, 2011
6. Saito G, Otawara Y, Ogawa A: A case report of ruptured internal carotid artery aneurysm with contralateral oculomotor nerve paresis. *No shinkei Geka* 33: 365-368, 2005
7. Kim SC, Chung J, Lim YC, Shin YS: Oculomotor nerve palsy associated with rupture of middle cerebral artery aneurysm. *J Korean Neurosurg Soc* 45: 240-242, 2009
8. Satyarthee GD, Mahapatra AK: Unusual neuro-ophthalmic presentation of anterior communicating artery aneurysm with

- third nerve paresis. *J Clin Neurosci* 11 : 776-778, 2004
9. White JB, Layton KF, Cloft HJ : Isolated third nerve palsy associated with a ruptured anterior communicating artery aneurysm. *Neurocrit Care* 7 : 260-262, 2007
 10. Fox JL : *Intracranial aneurysms*. Springer, New York, 1983, pp 163-183
 11. Tatezaki J, Higurashi M, Kushi Y, Shimohigoshi W, Asada H, Sakata K : Oculomotor nerve palsy associated with subarachnoid hemorrhage without aneurysmal compression : a case report. *Jpn J stroke* 37 : 327-331, 2015
 12. Suzuki K, Muroi, A, Kujiraoka Y, Takano S, Matsumura A : Oculomotor palsy treated by microvascular decompression. *Surg Neurol* 70 : 210-212, 2008
 13. Mulderink TA, Bendk BR, Yapor WY, Batjer HH : Third nerve paresis caused by vascular compression by the posterior communicating artery. *J Stroke Cerebrovasc Dis* 10 : 139-141, 2001
 14. Leivo S, Hernesniemi J, Luukkonen M, Vapalahti M : Early surgery improves the cure of aneurysm-induced oculomotor palsy. *Surg Neurol* 45 : 430-434, 1996