

## Another cause of treatable dementia: rapid cognitive improvement after carotid endarterectomy. Illustrative case

Mohammed Yassaad Oudrhiri, MD, PhD,<sup>1</sup> Akio Teranishi, MD,<sup>1</sup> Soshi Gotan, MD,<sup>1</sup> Hideo Nishi, MD,<sup>2</sup> Hiroki Kobayashi, MD,<sup>1</sup> Noriyuki Yahagi, MD,<sup>1</sup> Kaima Suzuki, MD, PhD,<sup>1</sup> Hidetoshi Ooigawa, MD, PhD,<sup>1</sup> and Hiroki Kurita, MD, PhD<sup>1</sup>

<sup>1</sup>Department of Cerebrovascular Surgery, International Medical Center, Saitama Medical University, Saitama Prefecture, Japan; and <sup>2</sup>Chichibu Neurosurgical Clinic, Saitama Prefecture, Japan

**BACKGROUND** Revascularization techniques in cervical internal carotid artery (ICA) stenosis are indicated to prevent the onset or recurrence of ischemic events in the setting of atherosclerotic carotid artery disease. Recent reports, case series, and comparative studies have suggested that revascularization techniques may also improve cognitive outcome in both symptomatic and asymptomatic patients, thus raising the question of whether another surgically treatable dementia has presented itself.

**OBSERVATIONS** A 70-year-old right-handed female with a history of hypertension, diabetes, and bilateral silent cerebral infarcts was evaluated for progressive cognitive impairment over a 1-year period, which was associated with a severe left cervical ICA stenosis. Carotid endarterectomy (CEA) was indicated as a revascularization technique, and the patient showed significant neurocognitive improvement as early as one month postoperatively, consistent with blood flow restoration to the left hemisphere on control imaging.

**LESSONS** This case serves as a reminder that CEA may improve the cognitive outcome of patients previously impaired by uncomplicated severe cervical ICA atherosclerotic disease, which can be another cause of treatable dementia. Further prospective studies may help to assess this potential benefit.

<https://thejns.org/doi/abs/10.3171/CASE23678>

**KEYWORDS** carotid endarterectomy; cognitive improvement; internal carotid artery; atherosclerotic disease

Neurocognitive decline is a growing concern when managing patients with asymptomatic but severe cervical carotid artery disease. Carotid endarterectomy (CEA) and other revascularization techniques aim primarily to prevent the onset or recurrence of ischemic events, but secondary neurocognitive improvement has been widely reported in the literature and may need to be considered as part of the treatment endpoints. Herein, we report a case of rapid neurocognitive improvement after CEA for severe asymptomatic cervical carotid artery disease and discuss this potential benefit of revascularization.

### Illustrative Case

A 70-year-old right-handed female with a past history of hypertension and diabetes was put on twice-daily aspirin for bilateral silent frontal and left occipital small infarcts that had been discovered during a

routine follow-up 4 years prior to her admission. Magnetic resonance angiography (MRA) showed mild bilateral atherosclerotic stenosis of the cervical internal carotid artery (ICA) but no significant intracranial artery stenosis, and serial yearly control magnetic resonance imaging (MRI) scans disclosed any further progression of the infarcts. Her cognitive function scores were assessed at 27 points using the Revised Hasegawa Dementia Scale<sup>1</sup> (HDS-R; borderline 0–30, cutoff 20/21) and were regularly controlled and remained stable. However, her physician pointed out a progressive neurocognitive decline within the past year, with her HDR-S score dropping to 11 points on the last follow-up, in line with progression of the left cervical ICA stenosis. The patient was then referred to our facility for management and further exploration.

On examination, the patient was alert with no neurological deficit. Her cognitive assessment was seamlessly evaluated using the

**ABBREVIATIONS** 3D = three-dimensional; CEA = carotid endarterectomy; CT = computed tomography; HDS-R = Revised Hasegawa Dementia Scale; ICA = internal carotid artery; MMSE = Mini-Mental State Examination; MoCA = Montreal Cognitive Assessment; MRA = magnetic resonance angiography; SPECT = single photon emission computed tomography.

**INCLUDE WHEN CITING** Published February 12, 2024; DOI: 10.3171/CASE23678.

**SUBMITTED** November 19, 2023. **ACCEPTED** December 11, 2023.

© 2024 The authors. CC BY-NC-ND 4.0 (<http://creativecommons.org/licenses/by-nc-nd/4.0/>)

HDS-R scale, and she showed severe impairment at 11 points. Radiological exploration revealed severe atherosclerotic stenosis of her left cervical ICA on both ultrasonography and three-dimensional (3D) computed tomography (CT) angiography (Fig. 1B), evaluated to more than 90% according to the North American Symptomatic Carotid Endarterectomy Trial method,<sup>2</sup> with no otherwise significant intracranial artery stenosis on MRA. Single photon emission computed tomography (SPECT) examination showed significant left hemispheric cerebral blood flow restriction (Fig. 1D and E).

With the thought that long-term decreased cerebral blood flow to her left dominant hemisphere was one of the causes of her progressive cognitive decline, a CEA was proposed, and the revascularization was uneventful. During the surgery, the plaque was found to be fibrous and could be totally resected without shunt placement. Postprocedural control imaging documented cervical carotid artery repermeabilization (Fig. 2B), and SPECT examination showed significant blood flow restoration to the left hemisphere (Fig. 2C and D).

Subsequently, the postoperative and follow-up periods were marked by a significant and rapid improvement of her neurocognition, reaching back to 26 points on the HDS-R at the 1-month evaluation. These results remained unchanged at the 3- and 6-month evaluations.

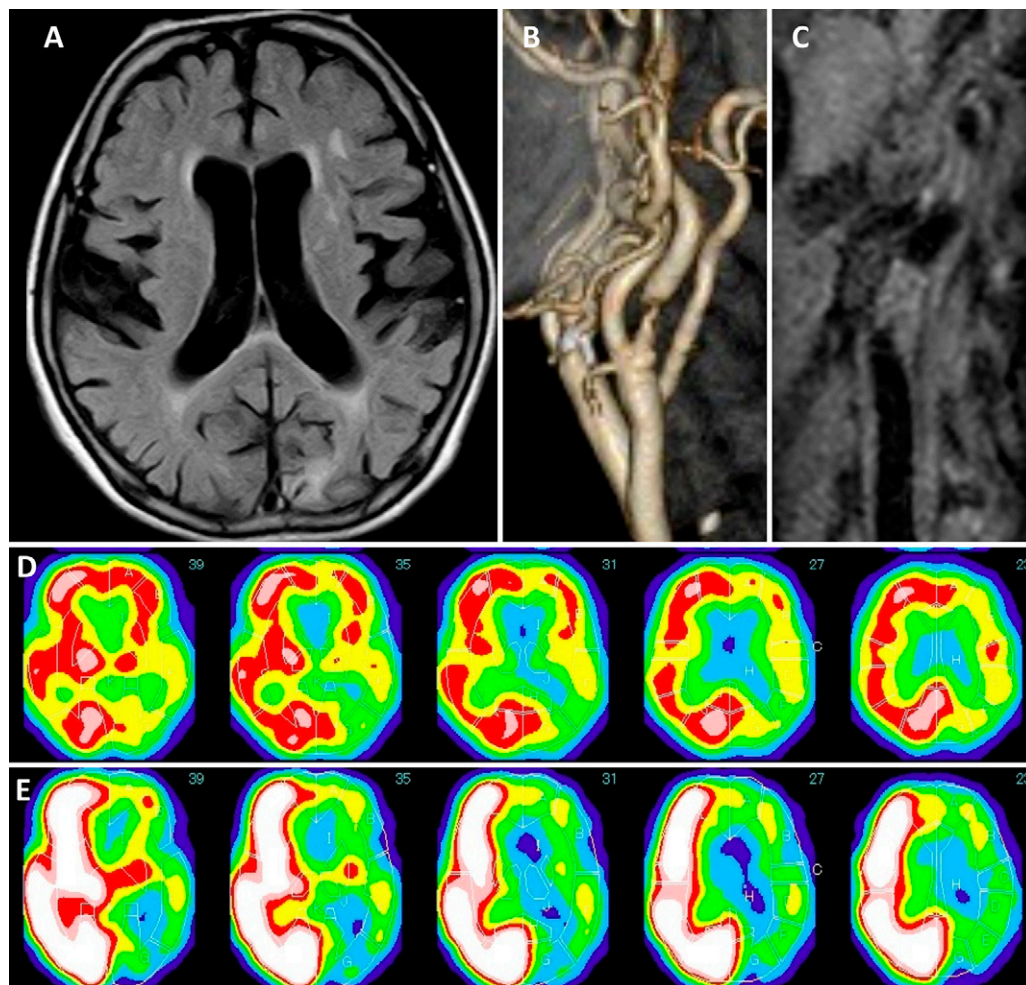
## Patient Informed Consent

The necessary patient informed consent was obtained in this study.

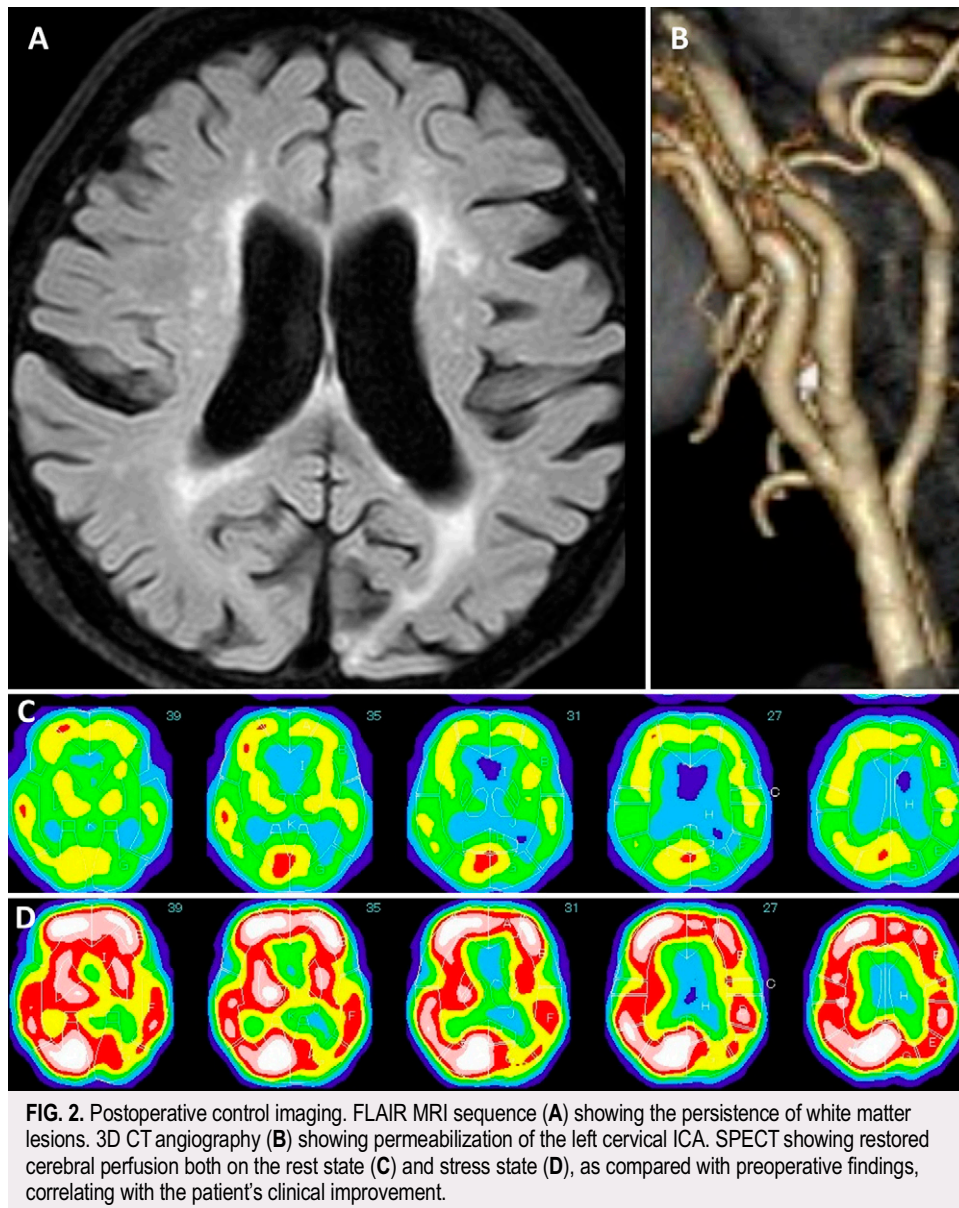
## Discussion

### Observations

Rapid neurocognitive improvement occurred in our patient after CEA as a revascularization technique for severe asymptomatic cervical carotid occlusive disease. While cervical carotid artery atherosclerotic disease is considered a major cause of ischemic stroke and transient ischemic attacks, surgical treatment indications have been defined in all the different guidelines depending on the presence or absence of stroke-related symptoms and the degree of stenosis,<sup>3–5</sup> with the aim of preventing the onset or recurrence of ischemic events. Therefore, patients were categorized as symptomatic if the carotid stenosis had caused ipsilateral cerebrovascular ischemic events in the preceding 6 months (to the ipsilateral eye or cerebral hemisphere) or as asymptomatic if none of the previous signs occurred during the preceding 6-month period. However, the debate is rising, as many reports have stressed the detrimental



**FIG. 1.** Preoperative findings. Fluid-attenuated inversion recovery (FLAIR) MRI sequence (A) showing white matter lesions and lacunar infarcts. 3D CT angiography (B) showing near-total occlusion of the left cervical ICA, from a homogeneous fibrous plaque on the injected MRI sequence (C). SPECT evaluation demonstrated relative and severe flow impairment to the left hemisphere on the rest state (D) and stress state (E), respectively.



effect of chronic vascular occlusion on brain structure and performance, revealing the importance and high incidence of cognitive impairment among both symptomatic and the so-called asymptomatic patients with severe cervical carotid artery atherosclerotic disease.<sup>6-8</sup>

Similar to intracranial occlusive pathology, the pathophysiology of this cognitive decline is multifactorial, as other known risk factors, when present, can contribute to this decline. A direct correlation between the hemodynamic effect of the stenosis and cognitive functioning has been found,<sup>9,10</sup> and it is believed that severe cervical carotid artery stenosis with diminished cerebrovascular reserve, along with repeated microemboli from atherosclerotic disease, will induce a chronic cerebral circulation insufficiency and cause an altered cerebral vasomotor response, resulting in white matter tract changes (demyelination and astrogliosis) that will induce neuronal loss with progressive brain atrophy, reduced cortical thickness and brain volume, with the final resultant of impaired cognition.<sup>10-14</sup>

Moreover, this impairment does not seem restricted to a condition in which the left dominant hemisphere is affected by the ipsilateral stenosis. In fact, in a large cohort of patients, Johnston et al.<sup>7</sup> showed that, not surprisingly, cognitive impairment and decline were significantly more common in patients with left-sided high-grade stenosis and of smaller and nonsignificant magnitude from the right-sided one. Conversely, recent studies<sup>6,10,12,15</sup> have suggested that the neurocognitive impairment can be observed regardless of dominance and laterality, as alterations were more likely to be bilateral, suggesting a dual hemispheric and generalized effect, and that a unilateral high-grade stenosis will induce signs specific to the ipsilateral side, which need to be addressed with the proper neurocognitive tests.

In this respect, heterogeneity or the lack of adaptability of the cognitive tests used to score and evaluate patients is considered as one important bias that prevents us from obtaining conclusive results in



assessing causality and relation to the occlusive pathology. Watanabe et al.<sup>16,17</sup> noted the differences in the results obtained using the Montreal Cognitive Assessment (MoCA) and Mini-Mental State Examination (MMSE) and the superiority of the MoCA in detecting mild cognitive impairment. Moreover, Johnston et al.<sup>7</sup> reported that the MMSE results were often normal in patients with right-sided hemispheric stroke or mass lesions, whereas Krambska et al.<sup>18</sup> used the Repeatable Battery for the Assessment of Neuropsychological Status to minimize the potential learning effect responsible for higher postoperative scores when other tests are used. This shows the need for more unified and adaptable tests and the use of common standards, per the Hachinski et al. recommendations.<sup>19</sup> In our case, we used the HDS-R, a highly used score in East Asian countries, which apart from its simplicity and reproducibility, has been proved to be accurate in screening for dementia and detecting moderate impairment in elderly patients.<sup>1,20</sup>

What adds more to the discussion is the reported reversibility of cognitive decline after treatment,<sup>21–24</sup> if an uncomplicated revascularization procedure had been achieved. In fact, this latter issue can be considered an ultimate factor for symptom reversibility, because perioperative hemodynamic changes and atherosclerotic or air microemboli can negate the benefits of revascularization. These benefits have been observed as early as 1 month postoperatively<sup>16,17,25</sup> and seem to be consolidated over time,<sup>8,16</sup> correlating with improved cerebral perfusion and hemodynamics,<sup>8</sup> with a superiority of CEA over carotid artery stenting or medical treatment alone.<sup>16,23</sup>

We believe that the duration of symptoms before revascularization may also affect the expected results and need to be addressed in further studies.

## Lessons

Cognitive decline from cervical carotid artery atherosclerotic disease is addressed in the literature as a possible curable symptom that may benefit from revascularization techniques and may serve as an indication for treatment. Although many controversies still exist, the effect of chronic cerebral blood flow impairment on brain function and cognition is being recognized, and early and long-lasting reversibility of symptoms has been reported. Neuropsychological assessment and control should be part of routine battery testing, as well as cervical carotid artery atherosclerosis screening.

Further well-designed studies will address issues related to the harmonization of neuropsychological tests, patient cohorts, the control of confounding risk factors, and postoperative complications to assess whether another surgically treatable dementia is in front of us.

## References

- Imai Y, Hasegawa K. The revised Hasegawa's Dementia Scale (HDS-R): evaluation of its usefulness as a screening test for dementia. *JHKC Psych*. 1994;2(SP2):20–24.
- U-King-Im JM, Trivedi RA, Cross JJ, et al. Measuring carotid stenosis on contrast-enhanced magnetic resonance angiography: diagnostic performance and reproducibility of 3 different methods. *Stroke*. 2004;35(9):2083–2088.
- Kern R, Nagayama M, Toyoda K, Steiner T, Hennerici MG, Shinohara Y. Comparison of the European and Japanese guidelines for the management of ischemic stroke. *Cerebrovasc Dis*. 2013;35(5):402–418.
- Biller J, Feinberg WM, Castaldo JE, et al. Guidelines for carotid endarterectomy: a statement for healthcare professionals from a special writing group of the Stroke Council, American Heart Association. *Stroke*. 1998;29(2):554–562.
- Bonati LH, Kakkos S, Berkefeld J, et al. European Stroke Organisation guideline on endarterectomy and stenting for carotid artery stenosis. *Eur Stroke J*. 2021;6(2):I-XLVII.
- Lazar RM, Wadley VG, Myers T, et al. Baseline cognitive impairment in patients with asymptomatic carotid stenosis in the CREST-2 Trial. *Stroke*. 2021;52(12):3855–3863.
- Johnston SC, O'Meara ES, Manolio TA, et al. Cognitive impairment and decline are associated with carotid artery disease in patients without clinically evident cerebrovascular disease. *Ann Intern Med*. 2004;140(4):237–247.
- Wang Q, Zhou M, Zhou Y, Ji J, Raithel D, Qiao T. Effects of carotid endarterectomy on cerebral reperfusion and cognitive function in patients with high grade carotid stenosis: a perfusion weighted magnetic resonance imaging study. *Eur J Vasc Endovasc Surg*. 2015;50(1):5–12.
- Lattanzi S, Carbonari L, Pagliariccio G, et al. Neurocognitive functioning and cerebrovascular reactivity after carotid endarterectomy. *Neurology*. 2018;90(4):e307–e315.
- Silvestrini M, Paolino I, Vernieri F, et al. Cerebral hemodynamics and cognitive performance in patients with asymptomatic carotid stenosis. *Neurology*. 2009;72(12):1062–1068.
- Zhou D, Meng R, Li SJ, et al. Advances in chronic cerebral circulation insufficiency. *CNS Neurosci Ther*. 2018;24(1):5–17.
- Marshall RS, Asllani I, Pavol MA, Cheung YK, Lazar RM. Altered cerebral hemodynamics and cortical thinning in asymptomatic carotid artery stenosis. *PLoS One*. 2017;12(12):e0189727.
- Liu Q, Bhuiyan MH, Liu R, et al. Attenuating vascular stenosis-induced astrogliosis preserves white matter integrity and cognitive function. *J Neuroinflammation*. 2021;18(1):187.
- Paraskevas KI, Faggioli G, Ancetti S, Naylor AR. Editor's choice— asymptomatic carotid stenosis and cognitive impairment: a systematic review. *Eur J Vasc Endovasc Surg*. 2021;61(6):888–899.
- Marshall RS, Festa JR, Cheung YK, et al. Cerebral hemodynamics and cognitive impairment: baseline data from the RECON trial. *Neurology*. 2012;78(4):250–255.
- Watanabe J, Ogata T, Higashi T, Inoue T. Cognitive change 1 year after CEA or CAS compared with medication. *J Stroke Cerebrovasc Dis*. 2017;26(6):1297–1305.
- Watanabe J, Ogata T, Hamada O, et al. Improvement of cognitive function after carotid endarterectomy—a new strategy for the evaluation of cognitive function. *J Stroke Cerebrovasc Dis*. 2014;23(6):1332–1336.
- Krámská L, Kovář M, Hrešková L, Jerie M. Neuropsychological performance after carotid endarterectomy. *J Integr Neurosci*. 2022;21(1):36.
- Hachinski V, Iadecola C, Petersen RC, et al. National Institute of Neurological Disorders and Stroke-Canadian Stroke Network vascular cognitive impairment harmonization standards. *Stroke*. 2006;37(9):2220–2241.
- Kim KW, Lee DY, Jhoo JH, et al. Diagnostic accuracy of mini-mental status examination and revised hasegawa dementia scale for Alzheimer's disease. *Dement Geriatr Cogn Disord*. 2005;19(5-6):324–330.
- Succar B, Zhou W. Does carotid intervention improve cognitive function? *Adv Surg*. 2023;57(1):267–277.
- Ghogawala Z, Amin-Hanjani S, Curran J, et al. The effect of carotid endarterectomy on cerebral blood flow and cognitive function. *J Stroke Cerebrovasc Dis*. 2013;22(7):1029–1037.
- Piegza M, Wiegkiewicz G, Wierzbą D, Piegza J. Cognitive functions in patients after carotid artery revascularization—a narrative review. *Brain Sci*. 2021;11(10):1307.
- Zhou W, Succar B, Murphy DP, et al. Carotid intervention improves cognitive function in patients with severe atherosclerotic carotid disease. *Ann Surg*. 2022;276(3):539–544.

25. Sridharan ND, Tzeng E, Patel S, et al. Carotid endarterectomy is associated with postoperative neurocognitive improvement in both symptomatic and asymptomatic patients. *J Vasc Surg.* 2020;72(1):E178.

### Disclosures

The authors report no conflict of interest concerning the materials or methods used in this study or the findings specified in this paper.

### Author Contributions

Conception and design: Oudrhiri, Teranishi, Nishi, Kobayashi, Yahagi, Suzuki, Kurita. Acquisition of data: Oudrhiri, Teranishi, Gotan, Kobayashi,

Yahagi, Suzuki. Analysis and interpretation of data: Oudrhiri, Kobayashi, Yahagi, Kurita. Drafting the article: Oudrhiri, Nishi, Kobayashi, Kurita. Critically revising the article: Nishi, Kobayashi, Kurita. Reviewed submitted version of manuscript: Nishi, Kobayashi, Kurita. Approved the final version of the manuscript on behalf of all authors: Oudrhiri. Statistical analysis: Kobayashi. Administrative/technical/material support: Kobayashi, Kurita. Study supervision: Nishi, Kobayashi, Ooigawa, Kurita.

### Correspondence

Mohammed Yassaad Oudrhiri: International Medical Center, Saitama Medical University, Saitama Prefecture, Japan. [yassaad.oudrhiri@gmail.com](mailto:yassaad.oudrhiri@gmail.com).