

Available online at www.sciencedirect.com

ScienceDirect

journal homepage: www.elsevier.com/locate/radcr

Case report

A rare brainstem hemorrhage due to incomplete transvenous embolization of the cavernous sinus dural arteriovenous fistula: A case report [☆],^{☆☆}

Yoshiki Mochizuki, Satoshi Iihoshi*, Eisuke Tsukagoshi, Shigen Kasakura, Shinya Kohyama, Hiroki Kurita

Department of Neurosurgery, International Medical Center, Saitama Medical University, 350-1298, Japan

ARTICLE INFO

Article history:

Received 19 May 2021

Revised 5 June 2021

Accepted 6 June 2021

Available online 5 July 2021

Keywords:

Dural arteriovenous fistula

Cavernous sinus

Transvenous embolization

Complication

Brainstem hemorrhage

ABSTRACT

Endovascular embolization is generally thought to be safe and effective for the cavernous sinus dural arteriovenous fistula (CS DAVF); however, some complications have been reported. We report an extremely rare brainstem hemorrhage associated with transvenous embolization (TVE) of CS DAVF. A 66-year-old man presented with right-sided conjunctival chemosis and exophthalmos. His brain magnetic resonance image showed right CS DAVF. Thus, emergent TVE was performed. Although his symptoms improved after the first TVE, magnetic resonance image showed brainstem edema, and venous congestion was suspected because of incomplete TVE. Second TVE was performed. Thereafter, computed tomography showed brainstem hemorrhage, resulting in the occurrence of right abducent nerve palsy, right-sided facial palsy, and ataxia. The patient's condition gradually improved, and a year has passed without recurrence. Incomplete TVE of CS DAVF can result in life-threatening complications, such as cerebral hemorrhage. To avoid these complications, the anatomical structure of the cavernous sinus should be understood accurately, and important drainage veins should be determined.

© 2021 The Authors. Published by Elsevier Inc. on behalf of University of Washington.

This is an open access article under the CC BY-NC-ND license

(<http://creativecommons.org/licenses/by-nc-nd/4.0/>)

Introduction

Cavernous sinus dural arteriovenous fistula (CS DAVF) can cause various symptoms such as chemosis, diplopia, bruit behind

the eyeball, and visual dysfunction. The goal of treatment for DAVF is complete occlusion of the arteriovenous shunt. For patients with severe symptoms, transvenous embolization (TVE) has been an efficient and safe treatment method

Abbreviations: DAVF, dural arteriovenous fistula; CS, cavernous sinus; CTA, computed tomography angiography; DSA, digital subtraction angiography; MRA, magnetic resonance angiography; MRI, magnetic resonance imaging; SOV, superior ophthalmic vein; SMCV, superficial middle cerebral vein; IPS, inferior petrosal sinus; SPS, superior petrosal sinus; TAE, transarterial embolization; TVE, transvenous embolization.

[☆] Acknowledgments: The authors would like to thank Enago (www.enago.jp) for the English language review.

^{☆☆} Competing interests: None.

* Corresponding author.

<https://doi.org/10.1016/j.radcr.2021.06.012>

1930-0433/© 2021 The Authors. Published by Elsevier Inc. on behalf of University of Washington. This is an open access article under the CC BY-NC-ND license (<http://creativecommons.org/licenses/by-nc-nd/4.0/>)

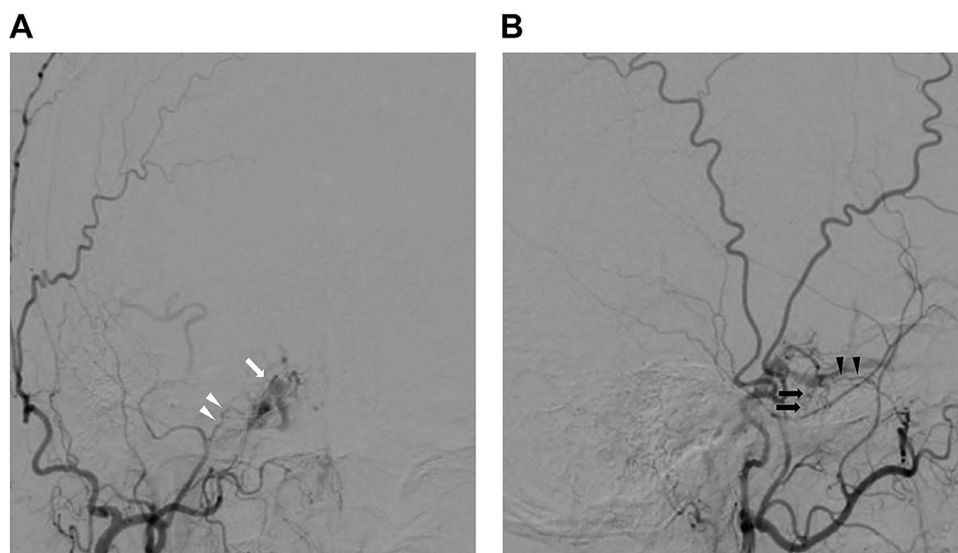


Fig. 1 – Right external carotid angiography A: Anterior right ECA angiogram showing early opacifying the right cavernous sinus (arrow) and right middle meningeal artery as a feeding artery (arrowhead). B: Lateral right ECA angiogram showing the accessory meningeal artery (black arrow) and foramen rotundum artery (black arrowhead). ECA, extracranial carotid artery.

[1]. However, some reports described life-threatening complications such as intracranial hemorrhage. We report the case of a patient with CS DAVF who underwent TVE and experienced a rare complication, that is intraprocedural brainstem hemorrhage.

Case report

A 66-year-old man presented with a history of conjunctival congestion, and exophthalmos of the right eye for several months. Magnetic resonance imaging (MRI) showed dilatation of the right superior ophthalmic vein on the T2-weighted image, and CS DAVF was suspected. Digital subtraction cerebral angiography showed Type II b right CS DAVF according to the Cognard classification [2] (Figs. 1A and B). Multiple dural branches from bilateral external carotid arteries were connected to a right cavernous sinus. Venous drainage was obviously through the superior ophthalmic vein, inferior ophthalmic vein, olfactory vein, pterygoid plexus, inferior petrosal sinus, and preopontine bridging vein (Fig. 2). Some cortical veins had been not only refluxed but also dilatated; thus, immediate treatment with TVE was performed several days after the diagnosis.

The first TVE of CS DAVF was performed via the right internal jugular vein and inferior petrosal sinus with the patient in a state of general anesthesia. A catheter was inserted into the right inferior petrosal sinus. We started coil packing from the superior ophthalmic vein to posterolateral compartment of cavernous sinus. Shunt points fed by accessory meningeal and foramen rotundum arteries were occluded by coil; however, its one fed by the middle meningeal artery did not completely disappear and the preopontine bridging vein also remained unobstructed. The embolization, although in-

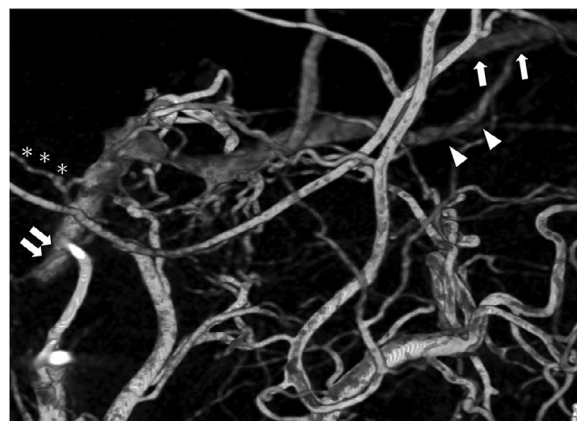


Fig. 2 – Right external carotid 3D rotational angiography Lateral right ECA 3D rotation angiogram showing some drainer veins include superior ophthalmic vein (arrow), inferior ophthalmic vein (arrow head), inferior petrosal sinus (double arrow), and preopontine bridging vein (asterisk). ECA, extracranial carotid artery.

complete, was stopped because of prolonged operative time (396 min), high radiation dose (4521 mGy), and extremely high dosage of contrast agent (179 ml).

After the first embolization, right conjunctival congestion had been improved; however, MRI showed high intensity at the right side of pons and right middle cerebellum peduncle on fluid-attenuated inversion recovery (Figs. 3A and C). Brainstem edema caused by venous stagnation was suspected. Due to CS DAVF recurrence, second TVE was performed emergently by coiling the embolization of the residual shunt point and preopontine bridging vein. Head MRI after the second TVE showed right-sided pons hemorrhage (Figs. 4A and B). Then, right ab-

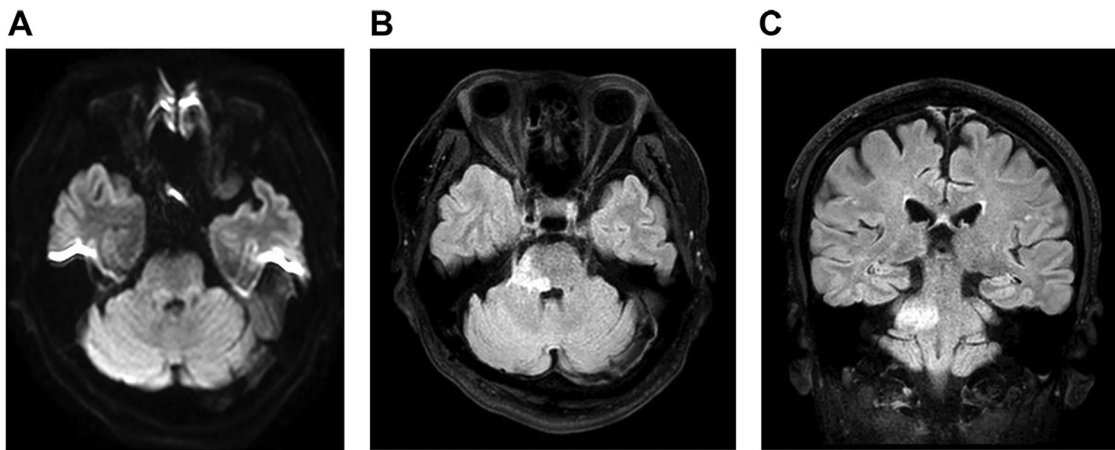


Fig. 3 – MRI imaging after 1st TVE A: Brain MRI after the first TVE showing isointensity signal at diffusion-weighted imaging (A) B and C: High intensity signal at fluid-attenuated inversion recovery indicated vasogenic edema due to venous congestion. MRI, magnetic resonance image; TVE, transvenous embolization.

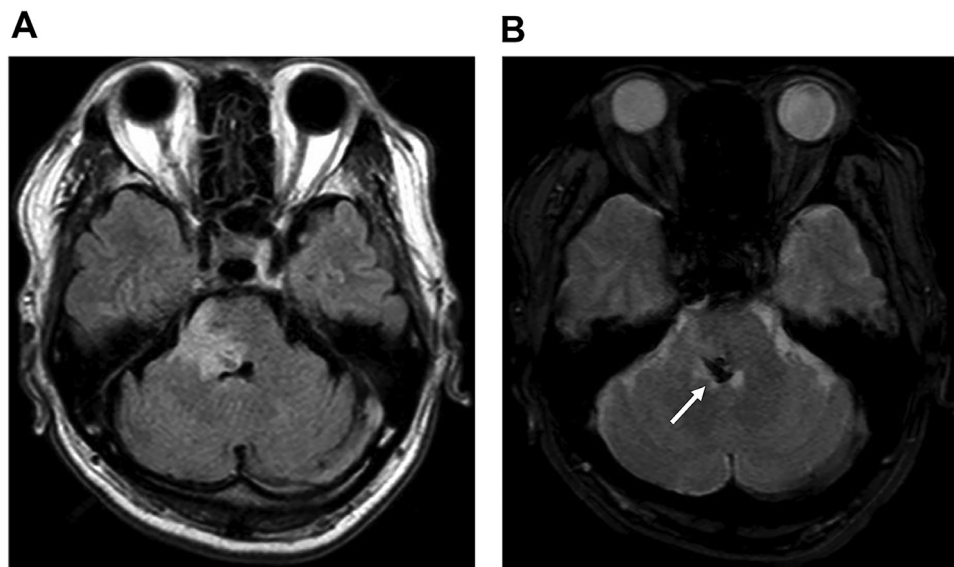


Fig. 4 – MRI imaging after 2nd TVE A: Fluid-attenuated inversion recovery image- Brain MRI after the second TVE showing deteriorated pons edema (A). B: T2* image- Arrow: pons hemorrhage MRI, magnetic resonance image; TVE, transvenous embolization.

ducent nerve palsy, right-sided facial palsy, and ataxia occurred after the second embolization. CS DAVF has not recurred, and the patient's symptoms gradually resolved and he was transferred to the rehabilitation hospital one month after the first embolization with modified Rankin Scale score of 3.

After 10 months, the patient has no complaints, except mild discomfort of the right eye (Fig. 5).

Discussion

The treatment for CS DAVF should be made with the drainage pattern and whether symptoms developed or not. Persistence

of the cortical venous reflux in CS DAVF yields an annual mortality rate of 10.4% [3]. Cortical venous drainage and aggressive presentation with intracranial hemorrhage or neurological deficits are strong predictors of poor natural history for CS DAVF [4]. Thus, these lesions require immediate treatment endovascularly or surgically.

Treatment options for CS DAVF include manual compression of the ipsilateral carotid artery, transarterial embolization of feeder vessels, and transarterial embolization. Endovascular treatment is the first-line treatment strategy for CS DAVF. TVE has been performed because of its efficacy and safety [1]. Recently, TAE with liquid adhesive such as N-butyl cyanoacrylate and Onyx are thought to be effective methods; however, these methods are contraindicated to TVE.

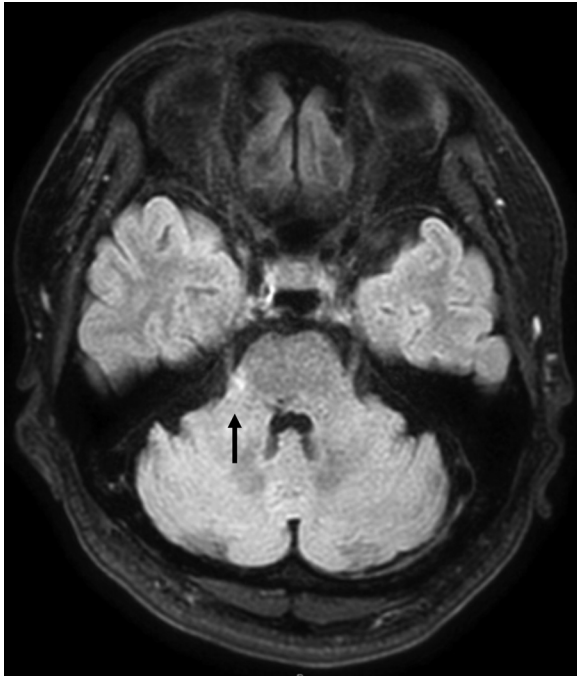


Fig. 5 – Postoperative MRI imaging at 10 mo Fluid-attenuated inversion recovery image. Brain MRI at 10 mo after the TVE showing decreased pons edema. MRI, magnetic resonance image; TVE, transvenous embolization.

Reported treatment complications in CS DAVF include deterioration of ocular motor dysfunction [5], transient ophthalmoplegia caused by sixth nerve dysfunction [6], cerebellar hemorrhage, and subsequent venous infarction [7]. Nakagawa et al. reported the causes of these complications are coil overpacking or residual dangerous venous drainage [8]. However, reports on cerebral hemorrhage as a complication of intravascular embolization of DAVF have been extremely limited. Moreover, only one report described brainstem hemorrhage associated with treatment [8] based on our literature search.

The reason why brainstem edema and hemorrhage caused is that partial obliteration of drainage pathways induced high intrasinus pressure and exacerbated reflux of the prepontine bridging vein into the brainstem [9].

In our case, increasing intra-cavernous sinus pressure after the incomplete embolization induced venous congestion of deep cerebral veins and brainstem edema. The second embolization achieved complete embolization, but the extremely high injection pressure of contrast materials resulted in exacerbated reflux of deep cerebral veins and brainstem hemorrhage.

The basal drainage veins including prepontine bridging vein can be often overlooked and also can be superimposed by cerebral arteries or other cerebral veins because they are light and tiny. Therefore, we should adequately evaluate and understand drainage veins before and during TVE of CS DAVFs.

We report a rare brainstem hemorrhage accompanied by TVE of CS DAVF. Incomplete TVE can result in life-threatening complications. Important drainage veins such as prepontine

bridging vein connected to the brainstem from the cavernous sinus are often overlooked. We should adequately evaluate and understand anatomical structure of cavernous sinus before and during TVE.

Data statement

The data used to support the findings of this study are available from the corresponding author upon request.

Ethical considerations

This case report does not disclose any identifiable information of any of the participant in any form. Hence, informed consent for publication and participation is not applicable here. Also, ethics committee approval is not applicable in this case. All study related procedures were carried out in accordance with the principles in Declaration of Helsinki.

REFERENCES

- [1] Klisch J, Huppertz HJ, Spetzger U, Hetzel A, Seeger W, Schumacher M. Transvenous treatment of carotid cavernous and dural arteriovenous fistulae: Results for 31 patients and review of the literature. *Neurosurgery* 2003;53:836–56 discussion 856.
- [2] Cognard C, Gobin YP, Pierot L, Bailly AL, Houdart E, Casasco A. Cerebral dural arteriovenous fistulas: Clinical and angiographic correlation with a revised classification of venous drainage. *Radiology* 1995;194:671–80.
- [3] van Dijk JM, terBrugge KG, Willinsky RA, Wallace MC. Clinical course of cranial dural arteriovenous fistulas with long-term persistent cortical venous reflux. *Stroke* 2002;33:1233–1236.
- [4] Zipfel GJ, Shah MN, Refai D, Dacey Jr RG, Derdeyn CP. Cranial dural arteriovenous fistulas: modification of angiographic classification scales based on new natural history data. *Neurosurg Focus* 2009;26:E14.
- [5] Aihara N, Mase M, Yamada K, Banno T, Watanabe K, Kamiya K. Deterioration of ocular motor dysfunction after transvenous embolization of dural arteriovenous fistula involving the cavernous sinus. *Acta NeurochirurgicaChir(Wien)* 1999;141:707–9 discussion 709.
- [6] Roy D, Raymond J. The role of transvenous embolization in the treatment of intracranial dural arteriovenous fistulas. *Neurosurgery* 1997;40:1133–41 discussion 1141.
- [7] Lee RJ, Chen CF, Hsu SW, Lui CC, Kuo YL. Cerebellar hemorrhage and subsequent venous infarction followed by incomplete transvenous embolization of dural carotid cavernous fistulas: a rare complication: case report. *J Neurosurg* 2008;108:1245–8.
- [8] Nakagawa I, Wada T, Nakagawa H, Hironaka Y, Kichikawa K, Nakase H. A rare brainstem hemorrhage during transvenous embolization of a cavernous dural arteriovenous fistula. *J Clin Neurosci* 2012;19:589–92.
- [9] Kiyosue H, Mori H, Sagara Y, Hori Y, Okahara M, Nagatomi H. Basal cerebral venous drainage from cavernous sinus dural arteriovenous fistulas. *Neuroradiology* 2009;51:175–181.